

# Occult carcinoma of breast presenting as axillary nodal metastasis – a case report

Jawahar Krishnaswamy<sup>1\*</sup>, Deivanayagam Shanmugam<sup>2</sup>, Vijay Kalimuthu<sup>3</sup>, Sanjai Venkatesh Somasukumar<sup>4</sup>

<sup>1</sup>Associate professor, <sup>2</sup>Professor, <sup>3</sup>Assistant Professor, <sup>4</sup>PG Student, Department of General Surgery, Saveetha Medical College And Hospital, Saveetha Nagar, Thandalam, Tamil Nadu.- 602105, INDIA.

Email: [drkjawahar@gmail.com](mailto:drkjawahar@gmail.com), [dr\\_deiva@yahoo.com](mailto:dr_deiva@yahoo.com), [viji\\_00765@yahoo.co.in](mailto:viji_00765@yahoo.co.in), [venkateshsomasukumar@gmail.com](mailto:venkateshsomasukumar@gmail.com)

## Abstract

We report the case of a 50-year-old woman with occult breast cancer who presented with a hard metastatic nodule in the left axilla. Histology identified a metastatic ductal carcinoma deposits in the lymph nodes, but mammography of left breast showed only diffuse thickening of skin and subcutaneous tissue. Left modified radical mastectomy was performed and histopathology revealed invasive ductal carcinoma 1mm x 1mm size with multiple axillary node metastasis.

**Key Word:** Occult carcinoma, axillary nodal metastasis.

## \*Address for Correspondence:

Dr. Jawahar Krishnaswamy, Associate professor, Department of General Surgery, Saveetha Medical College And Hospital, Saveetha Nagar, Thandalam, Tamil Nadu.- 602105, INDIA.

Email: [drkjawahar@gmail.com](mailto:drkjawahar@gmail.com)

Received Date: 08/11/2020 Revised Date: 16/12/2020 Accepted Date: 20/01/2021

## Access this article online

Quick Response Code:



Website:

[www.statperson.com](http://www.statperson.com)

Volume 11  
Issue 1

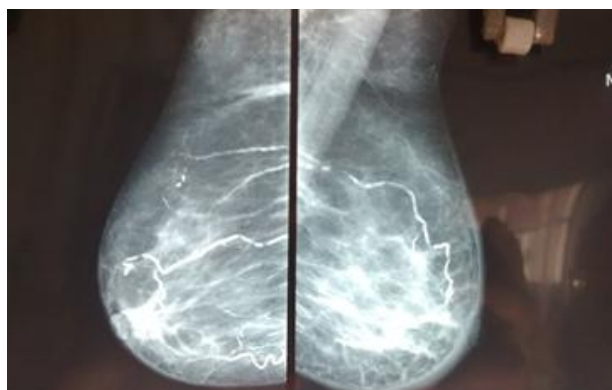
## INTRODUCTION

Occult breast cancer is an uncommon clinical entity accounting for less than 1% of all breast cancer patients. Malignant tumour of other sites like lung, thyroid, gastrointestinal tract, ovary, melanoma etc. also can occasionally metastasized to axilla, however, most common source of primary cancer in such cases is the ipsilateral breast unless otherwise proved. Diagnosis and treatment remain challenging in these patients. Relevant investigations to rule out other sites of malignancy and mastectomy with axillary clearance are recommended. Due to its rare occurrence and therapeutic dilemma, we decided to report our case who presented with a left axillary node without any evidence of primary malignancy.

## CASE PRESENTATION

A 50 year old known diabetic and hypertensive presented with left breast pain for three months with no palpable mass but mild edema was present in lower outer quadrant. She also had a mobile non-tender node in the left axilla. On investigating, the sonomammographic findings showed diffuse thickening of skin and subcutaneous tissue along the fascial planes with few axillary lymph nodes with a possibility of occult malignancy on the left side. Contralateral breast and axilla remains clear. Further, we proceeded with FNAC of left axillary node showed scattered clusters of round to oval epithelial cells with pleomorphic nuclei in a background of lymph nodes & hemorrhage with features suggestive of malignant deposits of ductal carcinoma.

Later, we proceeded with modified radical mastectomy of left breast. There was no lump in the mastectomy specimen and the tissue specimen sent for pathology where it was reported as infiltrating invasive ductal carcinoma of size 1 x 1 mm size with six axillary lymph node showed metastatic deposits left side. Immunohistochemistry showed oestrogen and progesterone receptors negative. Subsequently patient was subjected to chemotherapy and radiotherapy and she is under regular follow up.



**Figure 1:** Mammogram showing thickened skin and subcutaneous tissue

## DISCUSSION

Carcinomas of the lung, thyroid, stomach, colon, rectum, and pancreas have the potential to spread to the axillary lymph nodes; however, these metastases are rarely the first manifestations of disease. Non-palpable breast cancer presenting as axillary metastases is also rare, accounting for less than 0.5% of all breast cancers. However, in such cases it is important to consider occult breast cancer during the early stages; a correct diagnosis of breast cancer with axillary metastasis at stage II can be treated immediately by radical mastectomy. It is therefore difficult to decide on how extensively an investigation should be performed in order to exclude other possible origins of the metastasis. Immunohistochemical markers have proven useful for differentiating metastatic breast carcinoma from adenocarcinoma arising in other primary sites. Positive results from staining resected axillary lymph nodes for ERs and PRs are suggestive of breast cancer.

The treatment of occult breast cancer remains controversial. The traditional therapy of choice was radical or modified radical mastectomy. However, several recent studies have shown no statistically significant differences in outcome between mastectomy and more conservative treatments, such as limited resection and/or radiation. These findings suggest that breast-conserving therapy is an option for the treatment of occult breast cancer. In our case, our patient chose a modified radical mastectomy and a 1mm primary breast cancer was detected in serial sections of the total resected specimen. Other studies have reported that primary breast tumors could not be identified in approximately 30% of specimens from patients undergoing mastectomy for occult carcinoma. In such cases, the primary tumors in the breast may be too small to be detected by conventional pathological assessment. Although, in this case, the primary tumor was found in the lower outer quadrant of the breast, nearly one-half of all detectable primary occult breast tumors are

located in the upper outer quadrant. Prognoses of these patients are more or less similar to carcinoma breast stage II/III. Survival has not been shown to be dependent on whether the primary cancer in the mastectomy specimen was found or not.

## CONCLUSION

All isolated axillary node metastasis should be considered as occult primary breast cancer unless otherwise proved. Sonomammogram, MRI breast, FNAC of axillary mass along with other metastatic workup should be carried out in all cases. Axillary dissection with mastectomy followed by appropriate adjuvant therapy is recommended. Prognosis is comparable to stage II /III breast cancer.

## REFERENCES

1. Halsted WS. The result of radical operations for the cure of carcinoma of the breast. *Ann Surg* 1907;46:1–19.
2. Owen HW, Dockerty MB, Gray HK. Occult carcinoma of the breast. *Surg Gynecol Obstet* 1954;98:302–8.
3. Baron PL, Moore MP, Kinne DW, Candela FC, Osborne MP, Petrek JA. Occult breast cancer preserving with axillary metastases: updated management. *Arch Surg* 1990;125:210–4.
4. Kyokane T, Akashi-Tanaka S, Matsui T, Fukutomi T. Clinicopathological characteristics of non-palpable breast cancer presenting as an axillary mass. *Breast Cancer* 1995;2:105–12.
5. Edlow CW, Carter D. Heterotopic epithelium in axillary lymph nodes: report of a case and review of the literature. *Am J Clin Pathol* 1973;59:666–73.
6. Copeland EM, McBride CM. Axillary metastases from unknown primary sites. *Ann Surg* 1973;178:25–7.
7. Kemeny MM, Rivera DE, Terz JJ, Benfield JR. Occult primary adenocarcinoma with axillary metastases. *Am J Surg* 1986;152:43–7.
8. Iglehart JD, Ferguson BJ, Shinleton WW, Sabiston DC, Silva JS, Fetter BF, et al. An ultrastructural analysis of breast carcinoma presenting as isolated axillary adenopathy. *Ann Surg* 1982;196:8–13.
9. Bhatia SK, Saclarides TJ, Witt TR, Bonomi PD, Anderson KM, Economou SG. Hormone receptor studies in axillary metastases from occult breast cancers. *Cancer* 1987;59:1170–2.
10. Grunfest S, Steiger E, Sebek B. Metastatic axillary adenopathy: use of estrogen receptor protein as an aid in diagnosis. *Arch Surg* 1978;113:1108–9.
11. Haupt HM, Rosen PP, Kinne DW. Breast carcinoma presenting with axillary lymph node metastases: an analysis of specific histopathologic features. *Am J Surg Pathol* 1985;9:165–75.
12. Patel J, Nemoto T, Rosner D, Dao TL, Pickren JW. Axillary lymph node metastasis from an occult breast cancer. *Cancer* 1981;47:2923–7.
13. Rosen PP. Axillary lymph node metastases in patients with occult noninvasive breast carcinoma. *Cancer* 1980;46:1298–306.

14. Ozzello L, Sanpitak P. Epithelial stromal junction of intraductal carcinoma of the breast. *Cancer* 1970;26:1186–98.
15. Ellerbroek N, Holmes F, Singietary E, Evans H, Oswald M, McNeese M. Treatment of patients with isolated axillary nodal metastases from an occult primary carcinoma consistent with breast origin. *Cancer* 1990;66:1461–7.
16. Vilcoq JR, Calle R, Ferme F, Veith F. Conservative treatment of axillary adenopathy due to probable subclinical breast cancer. *Arch Surg* 1982;117:1136–8.
17. Feuerman, MD, Attie, JN, Rosenberg B. Carcinoma in axillary lymph nodes as an indicator of breast cancer. *Surg Gynecol & Obstet* 1962; 114: 5.
18. Westbrook KC, Gallager HS. Breast carcinoma presenting as an axillary mass. *Am J Surg* 1971; 122: 607.
19. Larsen RR, Sawyer KC, Sawyer RB, Torres RC. Occult carcinoma of the breast. *Am J Surg* 1964; 107: 553–555.
20. Osteen RT, Kopf G, Wilson RE. In pursuit of the unknown primary. *Am J Surg* 1978; 138: 494–498.
21. Fitts WT Jr, Steiner GC, Enterline HT. Prognosis of occult carcinoma of the breast. *Am J Surg* 1963; 106: 460.
22. Ashikari R, Rosen PP, Urban JA, Senoo T. Breast carcinoma presenting as an axillary mass. *Ann Surg* 1976; 183: 415–417.
23. Gershon-Cohen J, Ingleby H, Hermel MB. Occult carcinoma of the breast: Value of roentgenography. *Arch Surg* 1955; 70: 385.

Source of Support: None Declared  
Conflict of Interest: None Declared