

Efficacy of external fixation in high risk intertrochantric fracture of femur patients

Pawan Jadhav

Department of Orthopaedics, Indian Institute of Medical Science & Research College and Noor Hospital, Warudi, Taluka Badnapur, Dist. Jalna, Maharashtra, INDIA.

Email: drpawanjadhav@yahoo.co.in

Abstract

Introduction: Hip fractures are a leading cause of death and disability among the elderly. Treatment goals for this patient include early rehabilitation, restoration of the anatomic alignment of the proximal part of the femur and maintenance of the fracture reduction. Various treatment modalities have been explained by various authors. But the treatment of choice in high surgical risk elderly patients is not clear. **Aims and objectives:** To study the efficacy of external fixation in a group of high surgical risk elderly patients. **Materials and methods:** 20 cases of intertrochantric fracture of femur with ASA grade more than 2 were studied. First the fracture reduction was achieved using standard procedure. The reduction was confirmed in two planes that is, anteroposterior and lateral view on x-ray or c-arm. Schanz screws and connecting AO clamps were used as external fixators. The surgical time blood loss was recorded. Average hospital stay and post operative complications were recorded. **Results:** Majority of the patients were in grade III and IV of Tronzo fracture grading. According to the ASA grading majority (55%) of the patients were in ASA III grade. Superficial infection was the most common complication. In 7 cases malunion was observed. One case was reported as delayed union for which continuation of the fixator was needed for 14 weeks. There was no case of nonunion. The neck shaft angle in 13 patients was excellent (between 125 to 135 degrees). In two patients it was fair (between 110 and 125 degrees). In one patients it was poor (<110 degrees). The final outcome was not measured in 4 cases because they lost to follow-up. Two patients died in the course of treatment. The cause was unrelated to the fracture fixation. **Conclusions:** External fixation can be used as method of choice in high-risk geriatric patients with intertrochanteric fractures.

Key words: intertrochantric fracture of femur, external fixation, high risk patients.

Address for Correspondence:

Dr. Pawan Jadhav, Department of Orthopaedics, Indian Institute of Medical Science & Research College and Noor Hospital, Warudi, Taluka Badnapur, Dist. Jalna, Maharashtra, INDIA.

Email: drpawanjadhav@yahoo.co.in

Received Date: 01/10/2021 Revised Date: 10/11/2021 Accepted Date: 15/12/2021

Access this article online	
Quick Response Code:	Website: www.statperson.com
	Volume 12 Issue 1

INTRODUCTION

Hip fractures are a leading cause of death and disability among the elderly.^{1,2} Treatment goals for these patient include early rehabilitation, restoration of the anatomic alignment of the proximal part of the femur and maintenance of the fracture reduction.³ The sliding hip screw is widely used for fixation of intertrochantric fractures.^{4,5,6} Sliding hip-screw fixation is quick and

straightforward and it utilizes controlled impacting during weight bearing to stabilize the fracture, thus facilitating healing.⁷ However internal fixation using dynamic hip screw is associated with intraoperative blood loss and prolonged anesthesia. The elderly patients are high risk patients for surgery. Conservative treatment is a bad alternative as it is associated with mortality rate up to 60%. The functional results following fixation of intertrochanteric fractures with a sliding hip screw in osteoporotic bone are sometimes unsatisfactory because of failure of the fixation or failure to reestablish acceptable hip biomechanics.^{2,7} During the 1950s, external fixation was used to treat intertrochanteric fractures, but a high prevalence of postoperative complication such as pin loosening, infection and mechanical failure of the fixator caused surgeons to discontinue its use.⁸ Newly developed external fixators prompted us to reconsider external fixation as a suitable treatment option for high risk patients. Thus the present study was conducted with the assumption that, the combination of a minimally invasive

procedure and the external fixation would improve the clinical outcome in patients who are at high risk for osteosynthesis.

AIMS AND OBJECTIVES

To study the efficacy of external fixation in a group of high surgical risk elderly patients.

MATERIALS AND METHODS

The present study was conducted among the patients with intertrochanteric fracture and was unfit for anesthesia. Following inclusion and exclusion criteria was used to select the study subjects.

Inclusion criteria

- elderly patients with intertrochanteric fracture
- more than ASA II grade

Exclusion criteria

- A fracture secondary to a malignant tumor,
- Multiple fractures

By using above mentioned inclusion and exclusion criteria 20 patients of intertrochanteric fracture with associated co-morbid conditions like Poor cardiopulmonary, status, Uncontrolled diabetes mellitus, Cerebrovascular accidents, Compromised hepatic and renal function, Malignancy with disseminated metastasis or Severe anemia (hemoglobin < 6 g%) were selected.

After receiving approval from the institutional ethical committee and informed consent from the patients the study was started. All the patients were examined in detail and the findings were recorded on proforma. Tronzo grading was used to classify the fracture. In the preoperative medication, antibiotics such as cephalosporin (1gm iv) and amikacin (750mg iv) were administered preoperatively and then every eight hours for three days. Sedation was done in selected patients depending on the requirement.

Implants

- Schanz screws: in the present study two types of self drilling schanz screws were used with 9 inch length and 4.5 mm diameter each. One type had 6.5 mm thread diameter whereas other had 7.5mm thread diameter with self tapping tip.
- Connecting clamps: AO type and aesculap types were used.

Surgical procedure

RESULTS

Table 1: Distribution of patients according to their various details

Variable	No. of patients (n=20)	Percentage
Age group	70-80	40%
	60-70	30%
	50-60	25%

The patient was positioned supine on a fracture table, with all bony prominence well padded, with great care taken that there was no impingement of the table on labia or scrotum. First the fracture reduction was achieved using standard procedure. The reduction was confirmed in two planes that is, anteroposterior and lateral view on x-ray or c-arm. Local anesthesia was inducted before the procedure was performed. Richard's guide wire was inserted percutaneously at an angle of 125 to 135 degree 2 cm below the vastus ridge so that it was attempted to be in the center of the femoral head and neck according to the neck version. The position guide wire was confirmed with both anteroposterior and lateral x-rays. As this was the reference wire, negotiation of Schanz was possible in correct direction according to it. Stab incision taken and periosteum exposed by blunt dissection. The near cortex was drilled using 3.2 mm drill bit superior to the guide wire through which one Schanz screw with 6.5mm thread diameter was introduced in the neck and head. The screw was advanced till it reached the subchondral area and got maximal purchase in the cancellous bone. Second drill hole was made for second schanz screw distal to the subchondral level. This screw is positioned such that it rest on the calcar. The position for screws again confirmed on x-ray or image intensifier, two ordinary 4.5 mm schanz screws were inserted in the proximal femur 10cm apart such that two screw threads exit before the proximal cortex. It was confirmed that both the schanz screws, were in the femoral head and neck. Acceptability range of tip of schanz screws in femoral head was kept high as the included group of patients was low demanding patients. Mobilization was restricted to carry out activities of daily living only. Proximal two schanz screws were fixed to the connecting rods using specially designed connecting clamps which on loosening of its nut provide controlled collapse at the fractures site. Distal 2 schanz screws were attached to the connecting rods using ordinary AO or aesculap clamps. All clamps were tightened fully in the maximum possible abduction. Final x-ray of the fracture reduction and screw placement was taken and primary neck-shaft angle was measured and noted. Also, the total duration of surgery and amount of blood loss was noted. The connecting rods were kept as close to the skin as possible leaving area for the pin track dressing. The outcome of the procedure was noted and recorded.

Sex	40-50	1	05%
	Males	11	55%
	Females	9	45%
Tronzo grading	Grade I	0	00%
	Grade II	3	15%
	Grade III	8	40%
	Grade VI	7	35%
	Grade V	2	10%
	ASA I	0	00%
ASA grading	ASA II	0	00%
	ASA III	11	55%
	ASA IV	3	15%
	ASA V	6	30%

It was observed that majority of the patients with intertrochantric fracture were more than 60 years of age. 55% study subjects were male. The fractures were classified using Tronzo fracture grading. It was observed that majority of the patients were in grade III and IV. According to the ASA grading majority (55%) of the patients were in ASA III grade.

Table 2: Distribution of patients according to complication

Complication	No. of patients (n=20)	Percentage
Superficial infection	8	40%
Deep pin-tract infection	1	05%
Pin bending	2	10%
Pin breakage	1	05%
Pin cutout	2	10%
Malunion	7	35%
Delayed union	1	05%
Nonunion	0	00%

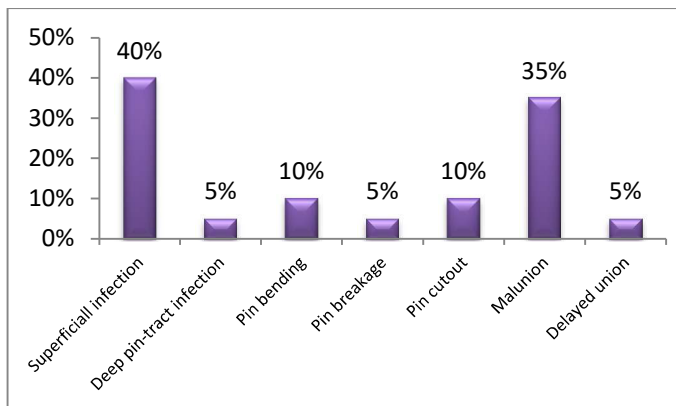


Figure 1: Distribution of patients according to complication

Superficial infection was the most common complication. A total of eight cases (40%) were having superficial type of infection and were treated with daily dressing and antibiotics. In one patient deep pin-tract infection was associated with continuous discharge from the pin tract site and active signs of infection from the pin tracts. Intravenous antibiotics and supervised dressings was done but was a case of chronic renal failure with diabetes mellitus with ischemic heart disease and died

due to septicemia. There were two cases of pin bending. One case developed pin breakage at the shaft thread level. In two cases pin cutout occurred. It is defined as varus collapse of the fracture with the femoral neck shaft angle less than 110 degrees and with extrusion of screw from femoral head exceeding 1mm. At the end of six months, neck shaft angle was measured. All angles above 125 degrees are labeled excellent union and below 110 degrees were labeled as poor union. Thus in 7 cases malunion was observed. One case was reported as delayed union for which continuation of the fixator was needed for 14 weeks. There was no case of nonunion.

Table 3: Distribution of patients according to outcome

Outcome	No. of patients (n=20)	Percentage
Excellent	13	65%
Fair	2	10%
Poor	1	05%
Lost follow up	4	20%
Died	2	10%

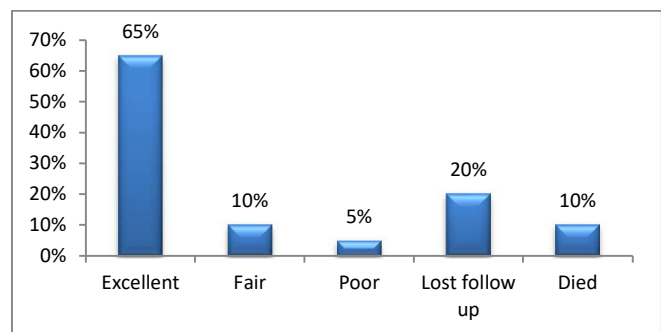


Figure 2: Distribution of patients according to outcome

In the present study the union rate was 100% and the average time of union was 6 weeks. The neck shaft angle in 13 patients was excellent (between 125 to 135 degrees). In two patients it was fair (between 110 and 125 degrees). In one patients it was poor (<110 degrees). The final outcome was not measured in 4 cases because they lost to follow-up. Two patients died in the course of

treatment. The cause was unrelated to the fracture fixation.

DISCUSSION

Longer life-span has been accompanied by an increase in the incidence of intertrochanteric fractures, which mainly occur in the elderly.⁹ Open reduction and internal fixation is the gold standard treatment in the fracture neck femur. But the morbidity and mortality rates are very high if the patients are elderly with significant co-morbid factors. Nonoperative treatment also involves prolonged immobilization and hospitalization, and it is also associated with many problems and high mortality¹⁰. Thus a method with the least blood loss, least procedure time and which ultimately facilitates early mobilization in the postoperative period for obtaining a perfect reduction of inter trochantric fracture among high-risk group is required.¹¹ Thus the present study was undertaken by using schanz screws and connecting AO clamps as external fixators in the management of inter trochantric fracture among high-risk group patients. Total 20 patients with various associated co morbid condition were included in the present study. Majority of the patients with intertrochantric fracture were more than 60 years of age. The average patient age was 65.5 years. 55% study patients were male. Tronzo described a classification based on reduction potential. He divided intertrochanteric fracture into 5 types, suggesting a specific mode of reduction for each type, prior to fixation. The fractures were classified using Tronzo fracture grading. It was observed that majority of the patients were in grade III and IV. With regard to co-morbidities, according to the American Society of Anesthesiologist (ASA) scale, eleven patients in were classified as ASA III and three patients were classified as ASA IV and six patients were of death-on- table consent group (ASA V). It was seen that reduction was easy to achieve by using routine methods. The procedure was performed under local anesthesia thus the complication due to general and spinal anesthesia was prevented. Average operative time was 27 minutes. Initially it was one hour which was reduced to 20 minutes with the use of newly designed implants. Procedure is less time consuming thus decreasing the change of postoperative wound complications. Negligible or minimal blood loss during procedure, no need for blood transfusions during or postoperatively. Average hospital stay was 3 days. The trochanteric frame used was small and it did not interfere with sitting, lying or walking in conventional clothes. Thus the patients were more comfortable. The complication rate was high in the present study. But majority (40%) was superficial

infection and was treated by antibiotics and daily dressing. There were two cases of pin bending. One case developed pin breakage at the shaft thread level. In two cases pin cutout occurred. In the present study 100% the union rate was achieved. The average time required for union was 6 weeks. At the end of six months, neck shaft angle was measured and the patients were categorized according to the angle from 90 up to 140 degrees. All angles above 125 degrees are labeled excellent and below 110 degrees were labeled as poor. It was observed that neck shaft angle in 13 patients was excellent. In two patients it was fair whereas in one patient it was poor. The final outcome was not measured in 4 cases because they lost to follow-up. Two patients died in the course of treatment but the cause was unrelated to the fracture fixation. In the present study we had excellent results in 65%, fair in 10% and poor results in 5% which were comparatively better with other international studies. Our concern was to have controlled collapse at the fracture site slide sliding screw and side plate. We tried to use modified AO type clamps for holding proximal schanz screws on loosening of which, the controlled collapse was expected. But the result was unsatisfactory. But still, we were able to maintain neck-shafts angle reasonably well in 65% of the patients (between 125 and 135 degrees) in whom the fracture ultimately united at 6 weeks. Sala milenkovic *et al*⁸ reported putting two parallel steinman pins in the femoral head up to the subchondral level and again withdrawing these two mm 5 mm back creating a path along which controlled collapse occurred following mobilization. Similar to various authors,^{12,13} we also observed advantages of external fixation. The external fixator implants were cost effective because they can be reused. It saves times and decreased the anesthetic risk as general and regional anesthesia was avoided. Minimal blood loss and no need for postoperative blood transfusion were required. It avoids the complication of conservative treatment (chest infection, deep venous thrombosis, bed sores etc.). It also avoids the complication of major open surgery in the form of blood loss, the risk of general and regional anesthesia, cost hospitalization, wound infection etc. Despite of these advantages, the external fixator has failed to become popular as most of the surgeons reported complications and infection being the most common. Cases of deep infection that required pin removal or repositioning have been reported.¹⁴ Vossinakis and Badras¹³ reported that pin track infection developed in 15 of their 50 patients (30%) treated with the Orthofix external fixator using standard pins. In our study also one case of pin-track infection was observed but the patients died due to septicemia because of associated co morbid condition. Even though from the above mentioned advantages and disadvantages, we

believe that the use of appropriate external fixation for the management of intertrochanteric fracture in elderly patients with poor health is a valuable alternative. External fixation is minimally invasive and causes no additional tissue trauma. In elderly patients of poor health (ASA 3 or 4), who are often malnourished, stable fixation without surgical trauma could be vital for a faster recovery and mobilization, with reduced morbidity and mortality.¹⁵

Thus external fixation decreases the morbidity and mortality related to non-operative treatment as it minimizes surgical damage and blood loss. It allows early mobilization and reduces the length of the hospital stay. So rehabilitation is easier in these patients with better functional result. It is also effective whenever early elective surgery is not possible.

CONCLUSIONS

External fixation can be used as method of choice in high-risk geriatric patients with intertrochanteric fractures.

REFERENCES

1. Christodoulou NA, Sdrenias CV. External fixation of select intertrochanteric fractures with single hip screw. Clin orthop. 2000;381:204-11
2. Larsson S. treatment of osteoporotic fractures. Scand J surg. 2002;91:140-6.
3. Baumgaertner MR. The peritrochanteric external fixator reduced pain, hospital stay, and mechanical complication in comparison with the sliding hip screw, J Bone joint surg Am. 2002; 84:1488.
4. Bridle SH, Patel AD, Bircher M, Calvert PT. Fixation of intertrochanteric fractures of femur. A randomised prospective comparison of the gamma nail and the dynamic hip screw, J Bone joint surg Br. 1991;73:330-4.
5. Hardy DC, Descamps PY, Krallis P, Fabeck L, Smets P, Bertens GL, Delince PE. Use of an intramedullary hip-screw compared with a fracture. A prospective, randomized study of one hundred patients. J Bone joint surg Am. 1998;80:618-30.
6. Perren SM, Allgoewer M, Schneider R, Maurice E. Manual of internal fixation; techniques recommended by the AO-ASIF Group. New York; Springer; 2001.
7. Jensen JS, Tondevold E, Mossing N. Unstable trochanteric fractures treated with the sliding screw-plate system. A biomechanical study of unstable trochanteric fractures. III. Acta orthop scand. 1978;49:392-7.
8. Sala Milenkovic, Milorad Mitkovic, Mile Radenkovic, Gesinir Mladenovic, Zoran Golubovic, Milos Stanjovic; surgical treatment of the trochanteric fractures by using the external and internal fixation methods.
9. Scott IH. Treatment of intertrochanteric fractures by skeletal pinning and external fixation. Clin orthop. 1957;10:326-34.
10. Christodoulou NA, Sdrenias CV. External fixation of select intertrochanteric fractures with single hip screw. Clin Orthop Relat Res. 2000; 381:204-211.
11. Tomak Y, Kacaoglu M, Piskin A et al. Treatment of intertrochanteric fractures in geriatric patients with a modified external fixator. Injury. 2005; 36:635-643.
12. Vossinakis IC, Badras LS. Management of peritrochanteric fractures in high-risk patients with an external fixation. Int Orthop. 2001; 25:219-222
13. Vossinakis IC, Badras LS. The external fixator compared with the sliding hip screw for peritrochanteric fractures of the femur. J Bone Joint Surg. 2002; 84-B:23-29
14. Dahl A, Varghese M, Bhasin VB. External fixation of intertrochanteric fractures of the femur. J Bone Joint Surg. 1991; 73-B:955-958
15. Navin Kumar Karn, Girish Kumar Singh, Pankaj Kumar, Mahi Pal Singh, Bikram Prasad Shrestha, Pashupati Chaudhary. Management of trochanteric fractures of the femur with external fixation in high-risk patients. International Orthopaedics. 2009; 33:785-788

Source of Support: None Declared
Conflict of Interest: None Declared